

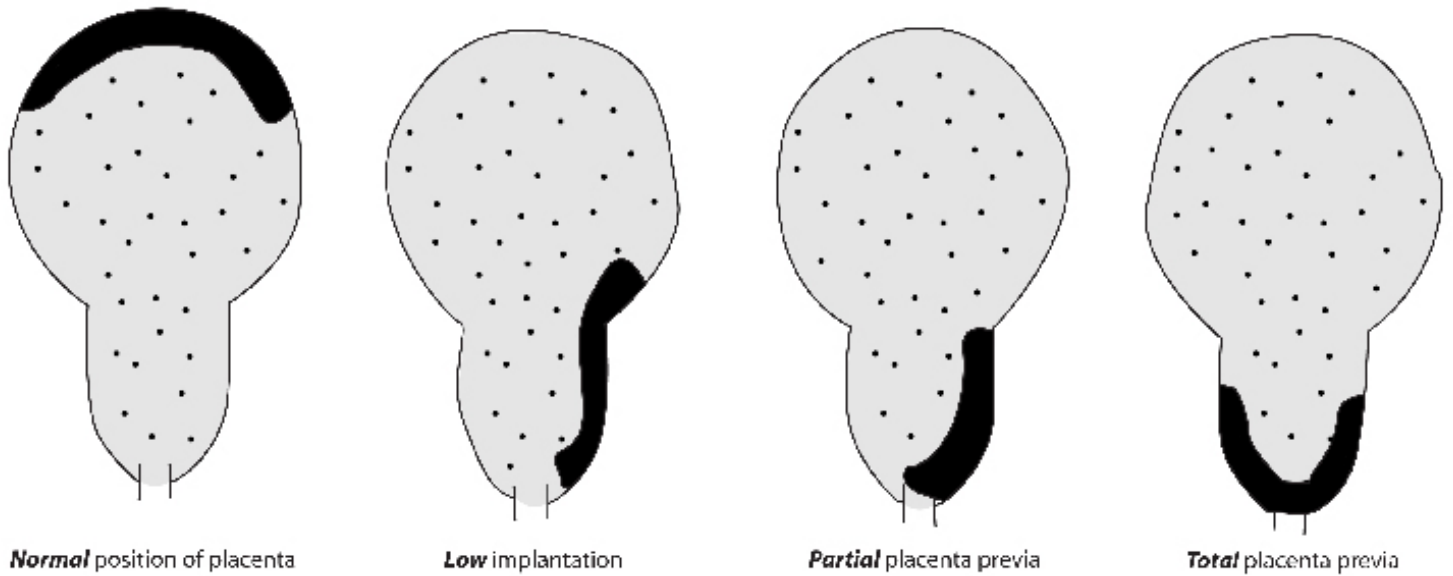FIGURE 3.4 PLACENTAL LOCATIONS

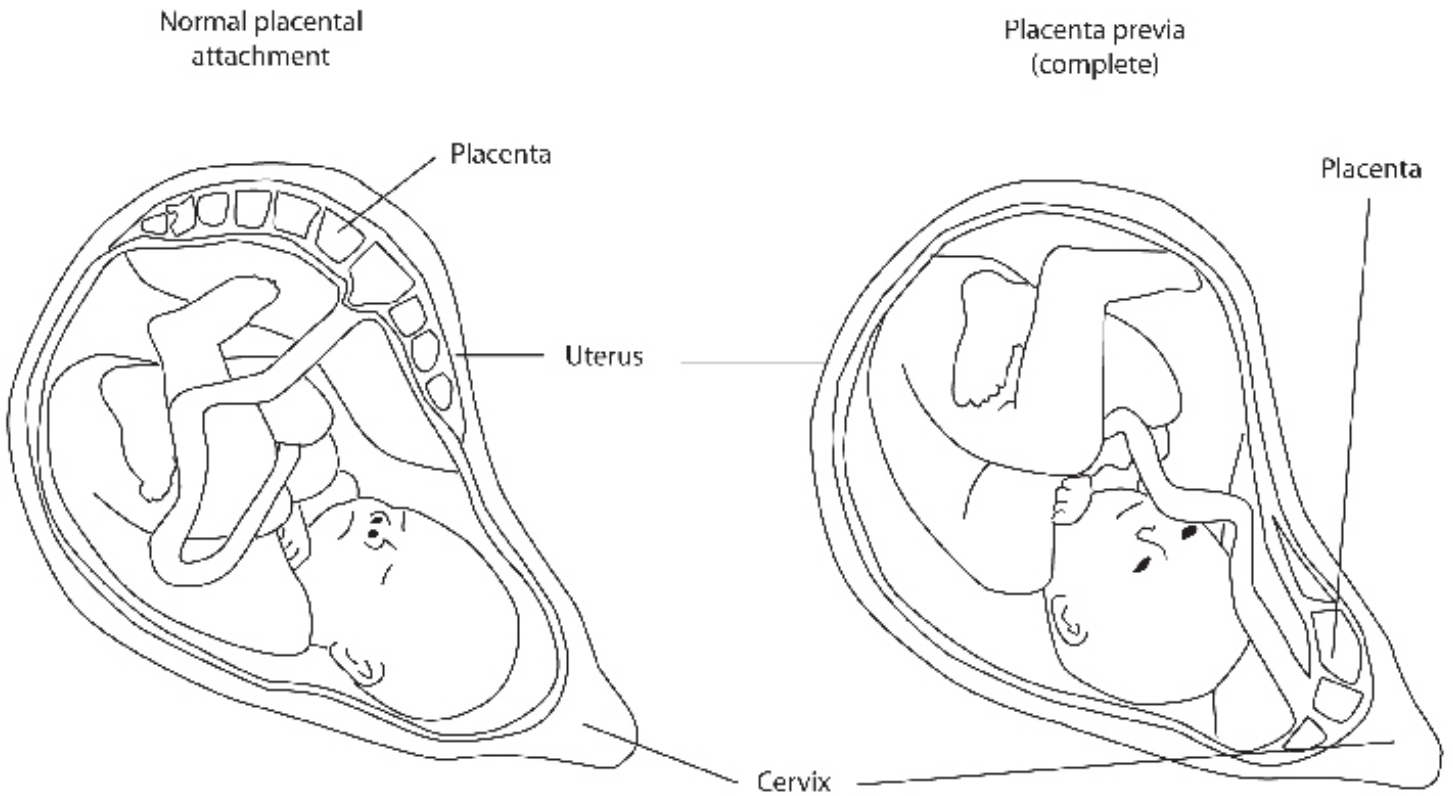


FIGURE 3.5 COMPARISON OF NORMAL PLACENTAL IMPLANTATION AND PLACENTA PREVIA.

- C. Increased discomfort—due to large, heavy uterus.
- D. Increased edema in vulva and legs.
- E. Shortness of breath.
- F. GI discomfort—heartburn, constipation.
- G. Susceptibility to *supine hypotensive syndrome*—due to compression of inferior vena cava and descending aorta while in supine position.

H. Medical diagnosis—procedures:

1. *Sonography*—to diagnose multifetal pregnancy, gross fetal anomaly, locate

placental site.

2. *Amniocentesis*—to diagnose anomalies, erythroblastosis.

III. Potential complications:

- A. Maternal respiratory compromise.
- B. Premature rupture of membranes (PROM) with prolapsed cord and/or amnionitis.
- C. Preterm labor.
- D. Postpartum hemorrhage—due to overdistention and uterine atony.